

Scientific Poster

C-0854 Bold functional magnetic resonance imaging: Impact on neurosurgical treatment planning

S. Morozov (Moscow/RU)

V. Sinitsyn (Moscow/RU)

S. Ternovoy (Moscow/RU)

Topic: Neuro / Miscellaneous

Purpose

Blood oxygenation level dependent functional magnetic resonance imaging (fMRI) turned out to be one of the most revolutionary MRI modalities. fMRI has enabled radiologists to perform human brain cortex mapping non-invasively and safely with high spatial and temporal resolution in clinical settings. This method has traveled a long way since its development in the early nineties of 20th century by Jack Belliveau who described fMRI in *Science* [1] mainly as a research tool. Due to the possibility to obtain valuable information about spatial relationship between brain lesions and eloquent cortex, fMRI has provided neuroradiologists and neurosurgeons with a useful tool for the selection of the operable patients, neurosurgical treatment planning and study of the cortical reorganization phenomena [2, 3]. fMRI will possibly substitute the Wada-test and become an integral part of neuronavigation systems used intraoperatively.

It is important to note that recent research works have revealed discrepancies between the results of patients studies with fMRI and MEG, EEG and PET [4]. Besides, fMRI-activated areas are highly dependent on the choice of paradigms and analysis thresholds [5]. These are one of the main pitfalls, which can hamper widespread introduction of fMRI into clinical practice. Thus, research works aimed at the assessment of fMRI in clinical environment are still needed.

The purpose of the study was to assess fMRI impact on the planning of the neurosurgical treatment of patients with space-occupying brain lesions. At the time when our project was initiated there was absolutely no fMRI experience in Russia. Hence, we designed the study consisting of two phases. The first one was investigational phase aimed at the evaluation of the capability of fMRI to locate functional areas of the cerebral cortex in healthy subjects. After the successful completion of the first phase we started the second phase to assess the contribution of fMRI to the planning of the neurosurgical treatment of patients with space-occupying brain lesions. Besides, we planned to compare success rate of fMRI studies performed on 1.0 T and 1.5 T MR scanners, motor tasks with rest state and without it.

Methods and Materials

The data used in the research were derived from the 105 fMRI studies of 34 healthy subjects (5-74 years old, mean age 38.6 years, SD 20.5 years) and 31 patients (5-77 years old, mean age 40.1 years, SD 21.2 years) mostly with centrally located space-occupying brain lesions. The results of fMRI studies of [26 patients](#)^{*1} have been used for the pre-operative treatment planning. fMRI was performed using whole body 1.0 T and 1.5 T MR scanners. Before imaging an automated shimming procedure was used to optimize B0 homogeneity.

A BOLD-sensitive T2*-weighted multislice echo-planar images were acquired with the following [parameters](#)^{*2}. For sensorimotor cortex mapping, axial sections were selected with the upper slice oriented tangentially to the brain convexity. For speech areas mapping, axial sections were selected parallel to the corpus callosum. Either motor or speech paradigms were selected depending on the location of brain lesions. For motor cortex localization simple finger tapping paradigms (with and without rest state) were used. For putative Brocas area activation word generation paradigm was used.

[The sample paradigm](#)^{*3} was arranged in a block design and consisted of "dummy" series for magnetic field stabilization (omitted from the post-processing of "raw" images), activity phases and control phases. Images acquired during well-known "hemodynamic lag" have been excluded from the post-processing as well. Duration of each task made up approximately 3-5 minutes.

[Post-processing of raw images](#)^{*4} was performed by means of standard software pre-installed on MR console. Sites of neuronal activation were identified by statistical analysis of the signal time course using z test and correlation method. In all cases high threshold ($p < 0.001$) was chosen to depict the most significant activation areas. Resulting functional maps were overlaid on morphological images (T1-weighted) and analyzed. "Signal intensity vs. time" graphs have been used for verification of activation areas. Results of the patients studies were discussed during joint meetings of radiologists and neurosurgeons.

Linked images in Methods and Materials:

Histopathologic diagnosis

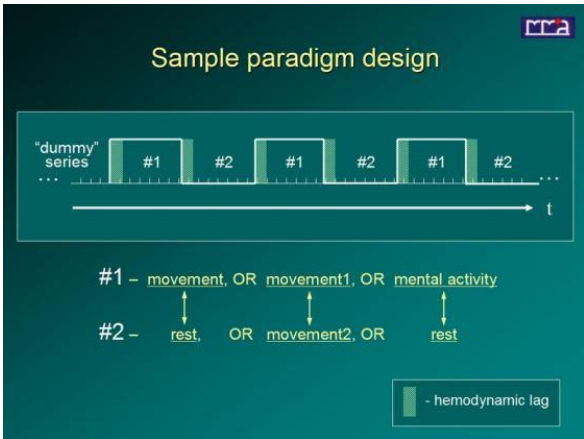
Histopathologic diagnosis	# of patients
Astrocytomas	8
Metastasis	7
Oligodendroglioma	3
Ependymoma	2
Meningioma	2
PNET	1
AVM	2
Cortical dysplasia	1
Total = 26	

*1:

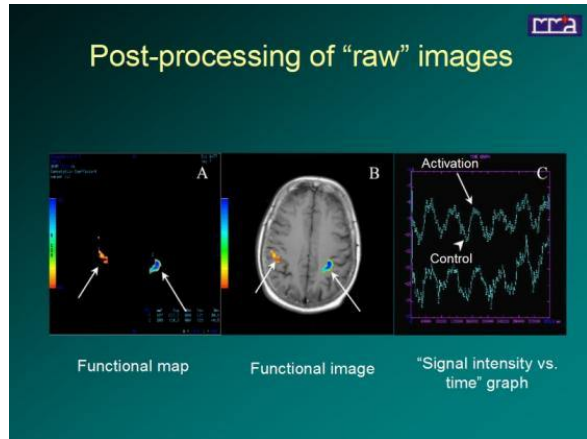
Echo-planar imaging procedure

Parameters	1.0 T	1.5 T
TE, ms	62	50
TR, ms	114	2000
FA, °	90	50
Slice thickness, mm	5	5
Number of slices	4-10	4-10
Field of view, mm	240	240
Matrix	64 x 64	64 x 64
Time of acquisition, s	80-120	120-210

*2:



*3:



*4:

Results

Studies success rate^{*5} was determined as a percentage of studies, which enabled localization of cortical activation areas in relation to the total number of studies. Difference in percentage of successful studies between the groups of healthy subjects and patients was not significant ($p>0.05$). Overall 93.3% of speech activation studies and 96.7% of motor activation studies were successful; 96.6% of studies performed at 1.5 T and 94.1% of studies performed at 1.0 T were successful. Overall studies success rate comes up to 96%.

The results of fMRI studies of 26 out of 31 patients have been used for pre-operative treatment planning (**see diagram**^{*6}). Our study has demonstrated that results of fMRI contributed to choice of the treatment method in 5 cases (19.2%), to craniotomy planning in 18 cases (69.2%). In 11.6% of cases the results of the studies were only taken into consideration. Thus, in 88.4% of cases results of fMRI significantly contributed to the planning of the neurosurgical treatment of patients with space-occupying brain lesions. **Follow-up**^{*7} of these patients has shown that 30.8% of them had had improvement of neurologic status post-operatively, neurologic status of 57.7% of these patients had not worsened post-operatively.

The motor paradigm without rest state (finger tapping alternating between right and left hand) was associated with the significantly smallest ($p<0.05$) quantity of **extracentral activation**^{*8}. Our results correspond well with the data obtained by the research group working under the guidance of Karsten Papke [6].

Clinical examples:

61 years old male **patient V.O.P.**^{*9} with slowly growing oligodendroglioma of the right hemisphere has been examined by means of fMRI with motor activation. It is important to note that the patient had no paresis. Decision about the possibility of neurosurgical treatment has been made on the basis of fMRI showing remoteness of the tumor from the sensorimotor cortex. The patient had no neurologic symptoms post-operatively.

56 years old male **patient N.V.B.**^{*10} with renal cancer metastasis has been examined by means of fMRI. Word generation and finger tapping paradigms have been used. Metastasis was found to be located in front of the primary motor cortex. This finding determines the possibility of the neurosurgical treatment. The right inferior frontal cortex shows activation in the contralateral location to the Broca's area. As a result of operation degree of paresis and aphasia has abated.

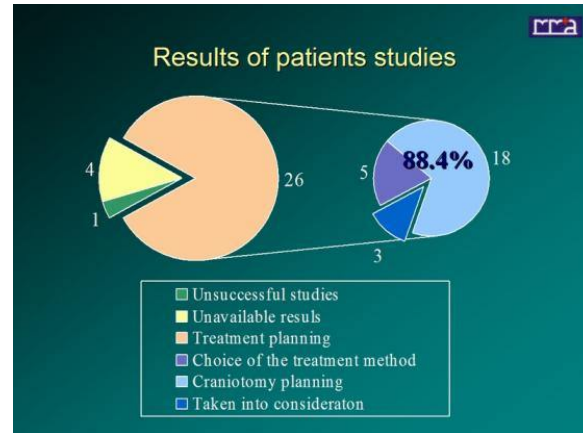
59 years old female **patient V.A.K.**^{*11} with astrocytoma (grade II) has been examined by means of fMRI with motor activation. The patient had tendinous hyperreflexia and increased muscular tonus of the right hand. According to fMRI data the tumor cannot be completely resected without damage to sensorimotor cortex. As a result of subtotal tumor resection patients neurologic status has not deteriorated.

Linked images in Results:

fMRI success rate

Study groups	Success rate
Subjects: • healthy subjects (n*=37) • patients (n=68)	97.3% 95.6%
Paradigms: • motor task (n=90) • speech task (n=15)	96.7% 93.3%
MR scanners: • 1.5 T (n=88) • 1.0 T (n=17)	96.6% 94.1%
Overall success rate (n=105)	96.2%

* number of studies



*5:

*6:

fMRI results in relation to post-operative neurologic status

fMRI impact	Number of patients	Post-operative neurologic status (at the time of discharge) in relation to initial neurologic status		
		Unchanged	Improved	Unknown
Choice of the treatment method	5	5 (100%)	-	-
Craniotomy planning	18	8 (44.4%)	8 (44.4%)	2 (11.2%)
Taken into consideration	3	2 (66.7%)	-	1 (33.3%)
Treatment planning	26	15 (57.7%)	8 (30.8%)	3 (11.5%)

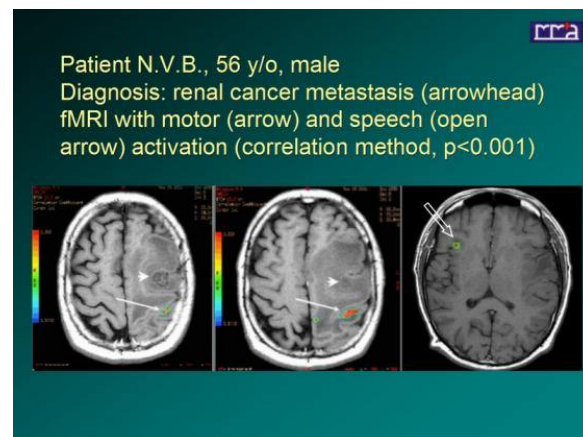
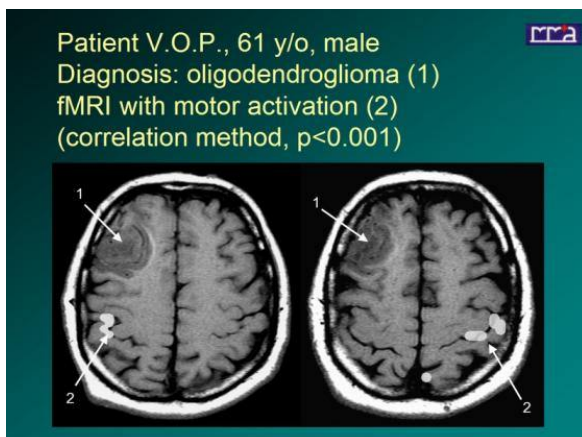
Selection of motor paradigm

Motor task	Extracentral activation
Left hand vs. rest	26.5±6.1%
Right hand vs. rest	20.1±10.5%
Left hand vs. right hand	7.0±5.7%

Significant difference, $p < 0.05$

*7:

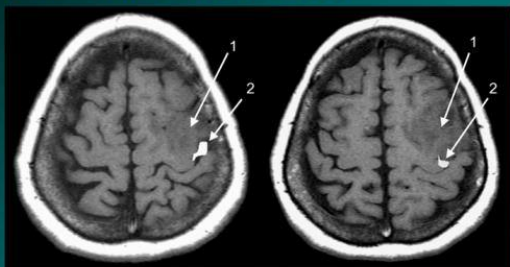
*8:



*9:

*10:

Patient V.A.K., 59 y/o, female
Diagnosis: astrocytoma grade II (1)
fMRI with motor activation (2)
(correlation method, $p < 0.001$)



*11:

Conclusion

So far our research has met with only limited success. Nevertheless from the above presented results it is clear that in the context of our study fMRI success rate depends neither on the group of subjects being studied (neurosurgical patients or healthy subjects), nor on the type of paradigm used (finger tapping or word generation), nor on the magnetic field strength (1.0 T or 1.5 T MR imaging system). Selection of the motor paradigm without rest state provides additional quality assurance. fMRI proved to be a valuable tool for the pre-operative assessment of the patients with space-occupying brain lesions.

References

1. Belliveau J.W. et al. Science 1991; 254: 716.
2. Roux F.E. et al. Neurochirurgie 2000; 46: 11.
3. Jack C.R., Jr. et al. AJNR 1999; 20: 1511.
4. Kober H. et al. Neuroimage 2001; 14: 1214.
5. Roux F.E. et al. Neurosurgery 2001; 49: 1145.
6. Papke K. et al. AJNR 2000; 21: 395.

Acknowledgements: professor Keith Thulborn, professor Hans-Jorgen Smith, professor Frode Laerum, professor Soren Jacob Bakke, Paulina Due-Tonnessen and Atle Bjornerud.

The Authors

Sergey Morozov, M.D.

Professor Sergey Ternovoj, M.D., Ph.D., Academician of Russian Academy of Medical Sciences

Professor Valentin Sinitsyn, M.D., Ph.D.

Department of Radiology, I.M. Sechenov Moscow Medical Academy, Moscow, Russian Federation

E-mail: radiology@mma.ru

Any information contained in this pdf file is automatically generated from digital material submitted to EPOS™ by third parties in the form of scientific presentations. References to any names, marks, products, or services of third parties or hypertext links to third-party sites or information are provided solely as a convenience to you and do not in any way constitute or imply ECR's endorsement, sponsorship or recommendation of the third party, information, product, or service. ECR is not responsible for the content of these pages and does not make any representations regarding the content or accuracy of material in this file.

As per copyright regulations, any unauthorised use of the material or parts thereof as well as commercial reproduction or multiple distribution by any traditional or electronically based reproduction/publication method is strictly prohibited.

You agree to defend, indemnify, and hold ECR harmless from and against any and all claims, damages, costs, and expenses, including attorneys' fees, arising from or related to your use of these pages.

Please note: Links to movies, ppt slideshows and any other multimedia files are not available in the pdf version of presentations.

www.ecr.org